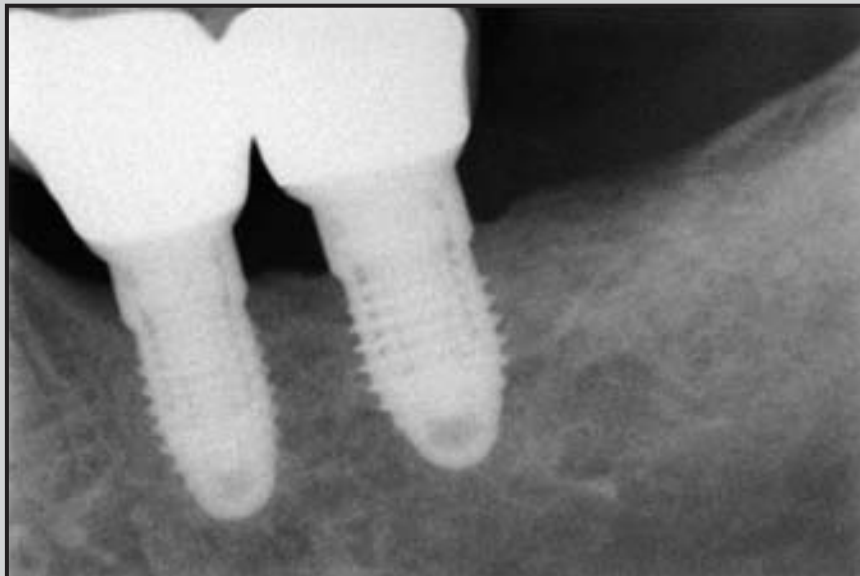
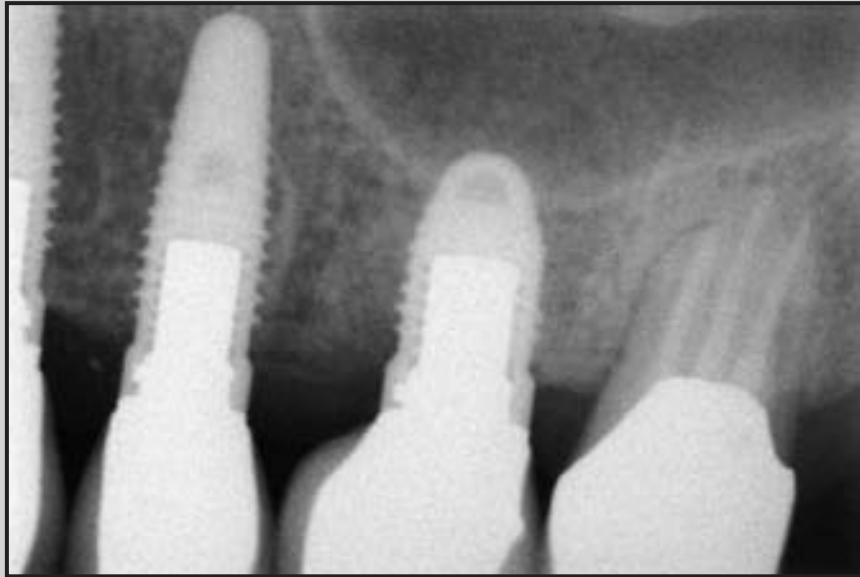
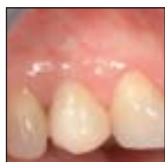## Multicenter Retrospective Analysis of 201 Consecutively Placed Camlog Dental Implants



Ilaria Franchini, DDS\*/Matteo Capelli, DDS\*/Luca Fumagalli, DDS\*  
Andrea Parenti, DDS\*/Tiziano Testori, MD, DDS\*\*

*Camlog tube-in-tube implants were introduced several years ago. This multicenter retrospective analysis evaluated the success rate of Root-Line and Screw-Line tube-in-tube implants in daily use. A total of 201 implants were placed in 96 patients with different indications and implantation procedures. Implants were analyzed retrospectively after a functional loading period of 12 to 78 months. At the end of the observation period, all but 1 implant fulfilled the success criteria, resulting in an implant survival rate of 99.5%. Individual case analysis of implants in special indications, such as immediate loading, short implants, and tilted implants, did not indicate any increased risk of implant failure. (Int J Periodontics Restorative Dent 2011;31:255–263.)*

\*Lecturer, Section of Implant Dentistry and Oral Rehabilitation, Department of Health Technologies, School of Dentistry, I.R.C.C.S. Galeazzi Institute, University of Milan, Milan, Italy.

\*\*Head, Section of Implant Dentistry and Oral Rehabilitation, Department of Health Technologies, School of Dentistry, I.R.C.C.S. Galeazzi Institute, University of Milan, Milan, Italy.

Correspondence to: Dr Ilaria Franchini, Viale Vittorio Veneto 8, 20124 Milan, Italy;  
email: [ilaria.franchini@dentimplant.it](mailto:ilaria.franchini@dentimplant.it).

The replacement of missing teeth with endosseous implants has become a standard treatment in dentistry. Over the past few years, various clinical studies have demonstrated the success of implant-supported fixed restorations by showing implant survival and success rates of 95% to 99% over 5 years.<sup>1-4</sup>

Today, the number of commercially available implant systems is constantly rising. The main differences between these systems arise from the clinical handling and macroarchitecture of the implant design, as well as the microarchitecture of the implant surface. The Camlog implant system (Camlog Biotechnologies) has introduced implants with an internal tube-in-tube connection between the abutment and implant, an antirotational connection, and a dual thermal acid-etched and particle-blasted rough surface (Promote, Camlog).

The tube-in-tube connection is a butt joint connection characterized by three symmetric grooves in the cervical portion of the implant and three corresponding cams on

the abutment. This connection type provides high precision and antirotational stability, as well as good force and torque distribution between the single components. In vitro studies have demonstrated high fatigue and fracture strength with this connection and significantly longer survival rates under dynamic loading compared to other connection systems.<sup>5</sup>

The aim of this study was to analyze retrospectively the survival rates and success of tube-in-tube implants in daily clinical practice. Particular focus was placed on special indications, such as immediate postextraction implant placement, immediate loading (within 72 hours), short implants (9-mm long), and tilted implants.

## Method and materials

All patients who consecutively received tube-in-tube implants (Promote Root-Line and Screw-Line implants) between March 2003 and September 2009 at four centers (three private practices and the University Department at the Galeazzi Institute, Milan, Italy) were included in this study. Implants ( $n = 259$ ) were placed in 115 patients by 4 different surgeons. Only patients corresponding to the American Society of Anesthesiologists health classification 1 or 2 were admitted to implant therapy. Patients were integrated in this analysis when prosthetic reconstructions were in place and had been loaded for at least 1 year.

## *Surgical procedure, prosthetic reconstruction, and follow-up*

The surgical procedure, implant placement, and pre- and postsurgical care were completed following the standard protocol of the manufacturer. In cases of dehiscence or crestal bone deficiencies at the site of implant placement, bone augmentation procedures were performed. In patients with insufficient bone height in the posterior region of the maxilla, sinus floor elevation was performed using either a lateral or crestal approach.

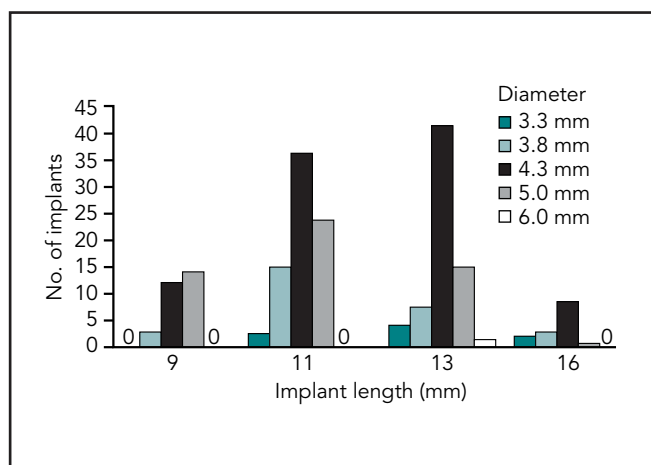
Implants healed in a submerged or nonsubmerged manner, depending on the individual plan. Implants were loaded either immediately (within 72 hours), early (within 2 months), or delayed (at least 8 weeks after surgery).

After functional loading, patients took part in a standardized recall protocol consisting of recalls every 6 months, which included radiographs, peri-implant sounding, and evaluation of clinical parameters, such as Plaque Index, Sulcus Bleeding Index, keratinized mucosa, possible recessions, suppuration, pain, and implant mobility. All clinical evaluations and data documentation took place in a strictly standardized manner corresponding to the requirements of clinical studies.

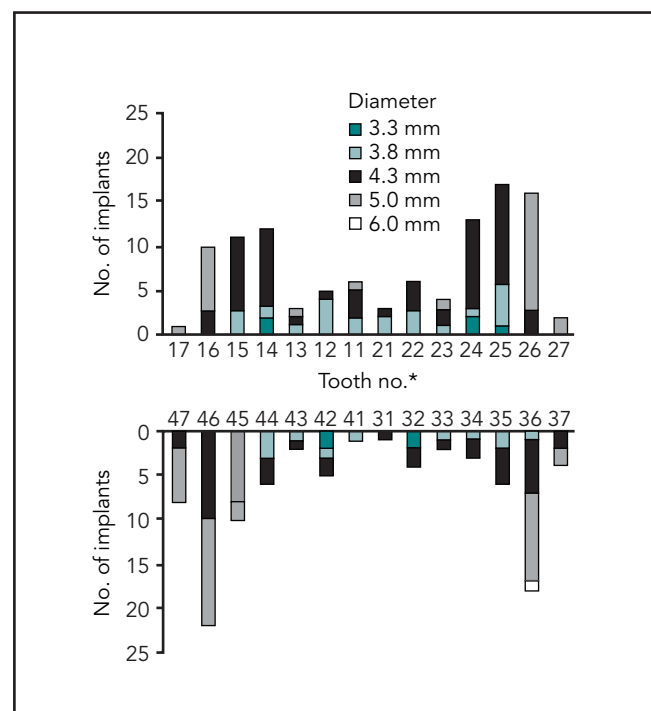
## *Evaluation*

Patients were analyzed with descriptive methods for the following parameters: indication for implant therapy; bone quality and quantity, according to the classification of Lekholm and Zarb<sup>6</sup>; implant position, diameter, and length; time of implant placement; concomitant surgical interventions; healing; loading protocol and type of reconstruction; and, finally, surgical, implant-related, and prosthetic complications. The implant survival rate was calculated as the number of implants in function at the end of the evaluation period. The implant success rate was evaluated according to Buser et al<sup>7</sup> (ie, absence of persistent subjective complaints such as pain, foreign body sensation, and dysesthesia; absence of peri-implant infections with suppuration; absence of mobility; and absence of continuous radiolucencies around the implant).

Statistical evaluation was performed using the software SPSS version 17.0 (IBM). Because of the data pool, only a descriptive statistical analysis was carried out by calculated means and standard deviations. For evaluation of implant survival rates, life tables were prepared.



**Fig 1** Distribution of implants by length and diameter.



**Fig 2** (right) Distribution of implant diameter in the maxilla and mandible according to their location. \*FDI tooth-numbering system.

## Results

### Patient pool

At the time of evaluation, 201 implants were loaded in 96 patients (56 women, 40 men; age range, 22.1 to 78.9 years; mean,  $54.4 \pm 12.9$  years) and had been in function for at least 1 year; these implants were therefore included in the retrospective analysis. Seventy-three patients were non-smokers, 12 were moderate smokers (< 10 cigarettes per day), and 11 patients were heavy smokers (> 10 cigarettes per day). Some patients ( $n = 35$ ) suffered parafunctions: 34 presented with bruxism and 1 patient was biting his fingernails severely.

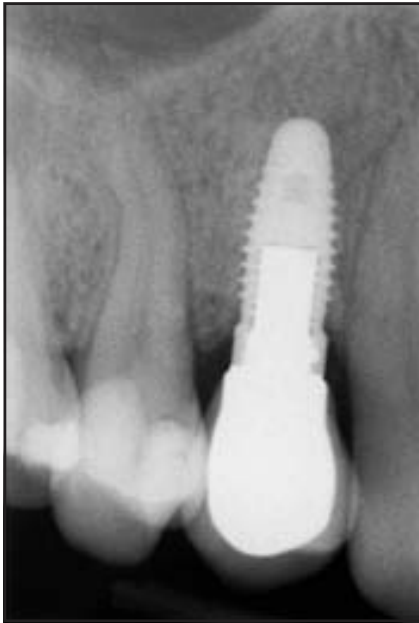### Implants and indications

One hundred ninety-two Root-Line and 9 Screw-Line implants were placed. The distribution of implant lengths and diameters is shown in Fig 1. One hundred nine implants (54.2%) were placed in the maxilla, and 92 (45.8%) were placed in the mandible (Fig 2). In the anterior region (first premolar to first premolar), 76 implants (37.8%) were inserted. One hundred fifty-eight implants (78.6%) were inserted in partially edentulous patients, 72 implants (35.8%) were placed in distal extension situations, and 86 implants (42.8%) were placed in interdental gaps. Forty-nine implants (24.4%) were single tooth replacements—

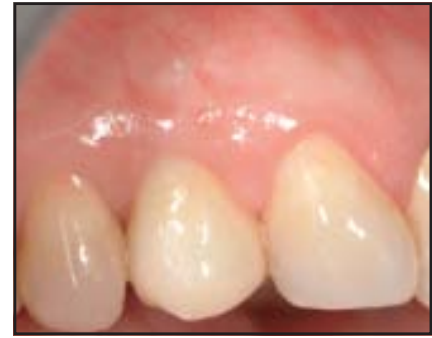42 of which were placed in single-tooth gaps and 7 in distal extension situations. Forty-three implants (21.4%) were inserted in completely edentulous arches. Thirty-seven implants (18.4%) were placed in fresh extraction sockets, and 7 implants (3.5%) were inserted in a tilted manner. Twenty-three implants (11.4%) were short implants (9 mm), most of which were placed in the mandible ( $n = 19$ , 20.6% of implants placed in the mandible).

### Surgical procedures

In most sites, a full-thickness flap was prepared (82.6%,  $n = 166$ ). Only 16.4% of implants ( $n = 33$ )



**Figs 3a and 3b** (left) Radiographic and (right) clinical esthetic outcomes of a single implant in the maxillary right first premolar region showing successful osseointegration after 24 months.



were placed using a flapless procedure; a split-thickness flap was used in 1% of implants ( $n = 2$ ). Half of the implants (50.7%,  $n = 102$ ) healed in a nonsubmerged manner, while the other half (49.3%,  $n = 99$ ) were left to heal submerged.

A total of 28.4% of implants ( $n = 57$ ; 4 were short implants) required additional bone augmentation procedures. Peri-implant bone defects were filled in 18.9% of implants ( $n = 38$ ), and a simultaneous sinus floor elevation procedure was needed in 9.45% of implants ( $n = 19$ ). Most sites undergoing sinus floor elevation were augmented using the lateral window technique ( $n = 16$ ); the osteotome technique was used in 3 sites.

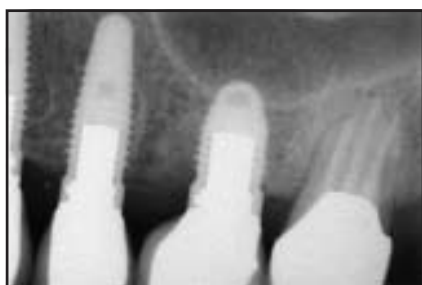#### *Prosthetic reconstruction*

Most implants were loaded after a minimum period of 8 weeks ( $n = 161$ , 80.1%); early loading ( $< 8$  weeks) was performed in 4% ( $n = 8$ ), and immediate loading (within 72 hours) in 15.9% of implants ( $n = 32$ ). One hundred eighty-four implants (91.5%) were restored with individual abutments and cemented crowns. Sixty-eight implants (33.8%) were single-tooth restorations either on single-gap implants ( $n = 49$ ; Figs 3a and 3b) or multiple adjacent implants ( $n = 19$ ); 133 implants (66.2%) were splinted multiple-tooth reconstructions. Seven implants supported a hybrid-screwed prosthesis, and 10 implants supported removable

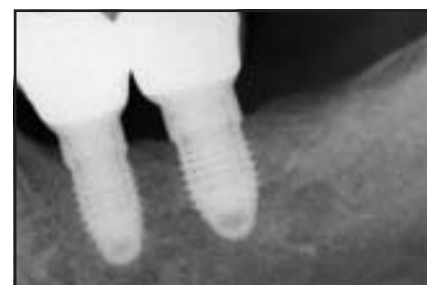overdentures, each on 2 implants. Of the 23 short implants, 19 (83%) were loaded using the delayed mode after more than 8 weeks of healing, while early loading was used for 3 implants and immediate loading was used for 1 implant. All but 2 short implants were restored with cemented splinted crowns (Figs 4a and 4b).

#### *Implant survival and success*

Of the 201 implants inserted, 200 were in function at the end of the evaluation period, resulting in an implant survival rate of 99.5%. Apart from the 1 implant that failed and had to be removed, all 200 implants



**Fig 4a** (left) Short 9-mm implant placed in proximity to the maxillary sinus and restored with a single crown. Result after 30 months.



**Fig 4b** (right) Short 9-mm implants placed in the posterior mandible in proximity to the mandibular nerve and restored with splinted crowns. Result after 18 months.

satisfied the success criteria described by Buser et al.<sup>7</sup> The observation period was  $43.1 \pm 15.9$  months (minimum, 12.6 months; maximum, 78.3 months).

### Complications

During sinus floor elevation, four perforations of the sinus membrane occurred (21%). The perforations were covered with a collagen membrane, and surgery was carried out. Healing and loading of the implants were uneventful.

One implant was lost 2 weeks after implantation and immediate loading in a patient who was a heavy smoker (> 20 cigarettes per

day). The implant was an immediate, single-tooth restoration inserted in a maxillary fresh extraction socket with residual periodontal infection. Additionally, a peri-implant bone defect had been filled with bone substitute.

In two patients, late peri-implantitis developed after loading. One instance of peri-implantitis occurred at a single implant site, a result of remaining residual cement after cementation of the definitive restoration. Treatment consisted of surgical debridement and a guided bone regeneration procedure. The second instance of peri-implantitis occurred on a short implant that was part of a multiple-implant reconstruction in the posterior mandible with poor keratinized soft tissue

around the implant. Peri-implantitis occurred 6 months after loading and was treated successfully with a resective surgical procedure. Prosthetic reloading took place after a healing period of 3 months.

Desealing of three crowns and two cases of screw loosening occurred, most likely a result of parafunction (bruxism). In two implant-supported crowns, the veneer reconstructions fractured and had to be replaced. All prosthetic complications were solved successfully.

Small soft tissue recessions ( $\leq 1$  mm) occurred on the buccal aspect of five implants inserted into postextraction sites; one was a short implant. However, the esthetic outcome was not compromised.

## Discussion

This multicenter retrospective analysis included patients treated with implant therapy under daily practice conditions. Therefore, the group of patients was not homogenous and included various dental situations, as well as different indications and implantation procedures. However, the recall evaluations were performed in a strictly standardized manner and followed the same protocol used on all implant patients.

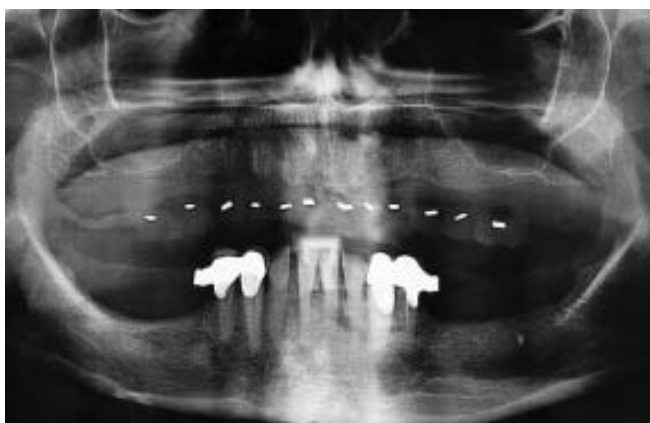
In this analysis, all implants but one fulfilled the success criteria at the end of the observation period, and the number of complications was very low. Surgical complications were managed uneventfully, and peri-implantitis and prosthetic complications were all solved successfully. The reasons for the one implant loss probably lie in the cumulative high risk in this individual case: fresh extraction socket in the maxilla, residual infection, immediate loading, heavy smoking, and poor oral hygiene. Smoking, in particular, is a well-known risk factor for implant survival and success,<sup>8,9</sup> even if studies on implants with dual thermal acid-etched and particle-blasted surfaces did not show reduced survival probabilities in smokers.<sup>10,11</sup> However, in this patient, a staged approach with delayed implant placement, longer healing times, and a delayed loading protocol might have improved implant success.

An overall implant survival rate of 99.5% was found in this analysis. In another study, similar survival

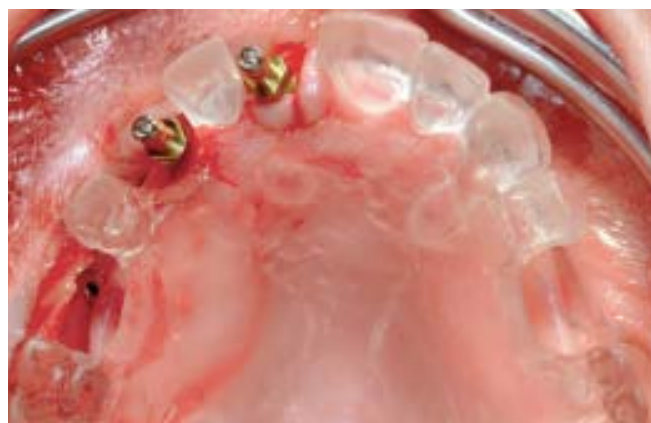rates of 99.8% for Root-Line and 98.1% for Screw-Line implants over 5 years were described.<sup>4</sup>

In recent years, immediate implant loading has been introduced to decrease the overall treatment time and the extent of surgical procedures.<sup>12,13</sup> Similar implant survival rates have been described for implants placed using immediate and delayed procedures.<sup>14–18</sup> Immediate loading offers predictable results in the mandible,<sup>19,20</sup> while problems arising from the anatomical and morphologic aspects of the maxilla have been reported.<sup>21</sup> In this multicenter analysis, most immediately loaded implants were placed in the maxilla (81%); one failed. The overall cohort was too small to analyze whether immediate implant insertion and immediate loading have a significantly higher risk of failure.

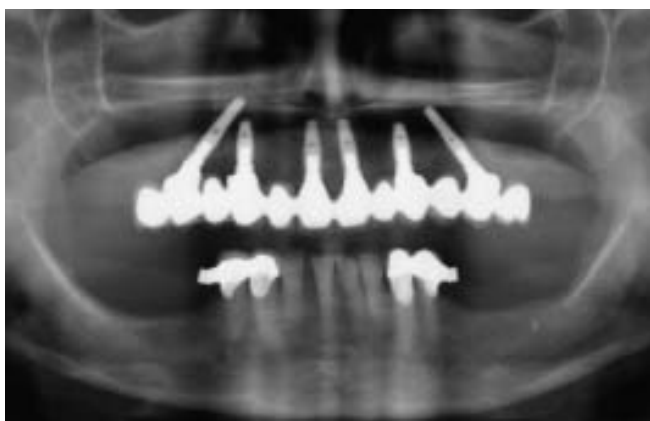A new concept to improve implant dentistry is the use of short implants to avoid bone augmentation procedures (see Figs 4a and 4b). Recent data on short implants with rough, microstructured surfaces revealed good survival rates, even after reduced healing times.<sup>10,22</sup> In this analysis, 2 of 23 short implants (9 mm) were involved in complications not related to implant length and were treated successfully. The question of whether short implants may bear a greater risk of implant failure in cases of peri-implantitis needs to be clarified in further studies. In this analysis, all short implants fulfilled the success criteria at the end of the observation period.



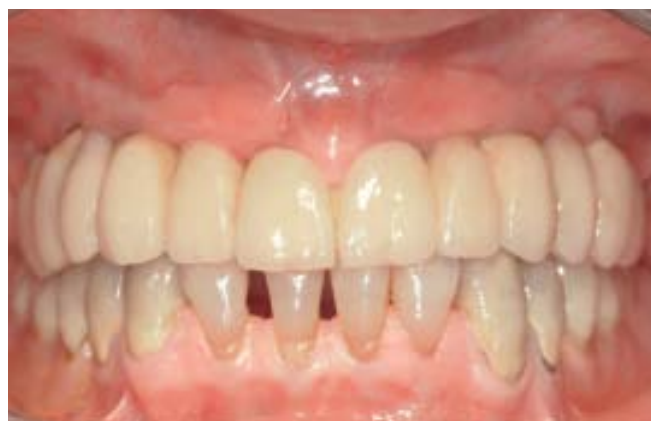**Fig 5a** Preoperative radiographic situation of an edentulous maxilla in a woman undergoing bisphosphonate treatment for osteoporosis.



**Fig 5b** Prosthetically driven implant placement with the help of a surgical guide. The four anterior implants were placed in an upright position, while the two bilateral distal implants were tilted posteriorly.



**Fig 5c** Radiograph taken at the 24-month follow-up after insertion of the definitive prosthesis with tilted distal implants.



**Fig 5d** Clinical outcome of the "all-on-six" full-arch restoration at the 24-month follow-up.

Placement of tilted implants in "all-on-six" or "all-on-four" rehabilitations is a new concept to overcome anatomical limitations, such as the mandibular canal, the genial foramen, or the maxillary sinus, in implant-supported rehabilitations of edentulous arches (Figs 5a to 5d). By tilting the distal implants poste-

riorly, the length of the cantilever is reduced, thereby making it possible to extend it distally without bone augmentation, sinus floor elevation, or nerve transposition procedures and improve implant length.<sup>23,24</sup> High implant and prosthesis survival rates have been reported for such restorations.<sup>25,26</sup> In this analysis, two



“all-on-four” and four “all-on-six” rehabilitations were used. In one, a tilted implant developed a small (< 1 mm) recession; in another, a small fracture of the cervical veneering surface occurred. No implant was lost. However, the overall cohort was too small to evaluate statistically the risk of complications with this type of rehabilitation.

### Conclusions

A tube-in-tube implant system was used in this multicenter analysis with different indications and treatment modes. Because of the limited number of implants, statistical comparison of the differences within treatments was not performed. Analysis of the individual implants and the possible reasons for complications and failures did not indicate a specific risk in any treatment. Under daily clinical practice conditions, the implant system used in this analysis resulted in high implant survival and success rates.

### References

1. Davarpanah M, Martinez H, Etienne D, et al. A prospective multicenter evaluation of 1,583 3i implants: 1- to 5-year data. *Int J Oral Maxillofac Implants* 2002;17:820–828.
2. Garlini G, Bianchi C, Chierichetti V, Sigurtá D, Maiorana C, Santoro F. Retrospective clinical study of Osseotite implants: Zero- to 5-year results. *Int J Oral Maxillofac Implants* 2003;18:589–593.
3. Astrand P, Engquist B, Dahlgren S, Gröndahl K, Engquist E, Feldmann H. Astra Tech and Brånemark system implants: A 5-year prospective study of marginal bone reactions. *Clin Oral Implants Res* 2004;15:413–420.
4. Nelson K, Semper W, Hildebrand D, Ozyuvaci H. A retrospective analysis of sandblasted, acid-etched implants with reduced healing times with an observation period of up to 5 years. *Int J Oral Maxillofac Implants* 2008;23:726–732.
5. Steinebrunner L, Wolfart S, Ludwig KL, Kern M. Implant-abutment interface design affects fatigue and fracture strength of implants. *Clin Oral Implants Res* 2008;19:1276–1284.
6. Lekholm U, Zarb G. Patient selection and preparation. In: Brånemark P-I, Zarb G, Albrektsson T (eds). *Tissue-Integrated Prostheses*. Chicago: Quintessence, 1985: 1199–1211.
7. Buser D, Ingmarsson S, Dula K, Lussi A, Hirt HP, Belser UC. Long-term stability of osseointegrated implants in augmented bone: A 5-year prospective study in partially edentulous patients. *Int J Periodontics Restorative Dent* 2002;22:109–117.
8. Wallace RH. The relationship between cigarette smoking and dental implant failure. *Eur J Prosthodont Restor Dent* 2000;8:103–106.
9. Buser D, Martin W, Belser UC. Optimizing esthetics for implant restorations in the anterior maxilla: Anatomic and surgical considerations. *Int J Oral Maxillofac Implants* 2004;19(suppl):43–61.
10. Grunder U, Gaberthuel T, Boitel N, et al. Evaluating the clinical performance of the Osseotite implant: Defining prosthetic predictability. *Compend Contin Educ Dent* 1999;20:628–640.
11. Kumar A, Jaffin RA, Berman C. The effect of smoking on achieving osseointegration of surface-modified implants: A clinical report. *Int J Oral Maxillofac Implants* 2002;17:816–819.

12. Nkenke E, Fenner M. Indications for immediate loading of implants and implant success. *Clin Oral Implants Res* 2006; 17(suppl 2):19–34.
13. Cochran DL, Morton D, Weber HP. Consensus statements and recommended clinical procedures regarding loading protocols for endosseous dental implants. *Int J Oral Maxillofac Implants* 2004;19 (suppl):109–113.
14. Rosenquist B, Grenthe B. Immediate placement of implants into extraction sockets: Implant survival. *Int J Oral Maxillofac Implants* 1996;11:205–209.
15. Chen ST, Darby IB, Adams GG, Reynolds EC. A prospective clinical study of bone augmentation techniques at immediate implants. *Clin Oral Implants Res* 2005; 16:176–184.
16. Quirynen M, Van Asshe N, Botticelli D, Berglundh T. How does the timing of implant placement to extraction affect outcome? *Int J Oral Maxillofac Implants* 2007;22(suppl):203–223 [erratum 2008; 23:56].
17. Botticelli D, Renzi A, Lindhe J, Berglundh T. Implants in fresh extraction sockets: A prospective 5-year follow-up clinical study. *Clin Oral Implants Res* 2008;19: 1226–1232.
18. Schropp L, Isidor F. Timing of implant placement relative to tooth extraction. *J Oral Rehabil* 2008;35(suppl 1):33–43.
19. Testori T, Del Fabbro M, Galli F, Francetti L, Taschieri S, Weinstein RL. Immediate occlusal loading the same day or the day after implant placement: Comparison of 2 different time frames in total edentulous lower jaws. *J Oral Implantol* 2004; 30:307–313.
20. Testori T, Meltzer A, Del Fabbro M, et al. Immediate occlusal loading of Osseotite implants in the lower edentulous jaw. A multicenter prospective study. *Clin Oral Implants Res* 2004;15:278–284.
21. Bosse LP, Taylor TD. Problems associated with implant rehabilitation of the edentulous maxilla. *Dent Clin North Am* 1998;42:117–127.
22. Salvi GE, Gallini G, Lang NP. Early loading (2 or 6 weeks) of sandblasted and acid-etched (SLA) ITI implants in the posterior mandible. A 1-year randomized controlled clinical trial. *Clin Oral Implants Res* 2004;15:142–149.
23. Krekmanov L, Kahn M, Rangert B, Lindström H. Tilting of posterior mandibular and maxillary implants for improved prosthesis support. *Int J Oral Maxillofac Implants* 2000;15:405–414.
24. Krekmanov L. Placement of posterior mandibular and maxillary implants in patients with severe bone deficiency: A clinical report of procedure. *Int J Oral Maxillofac Implants* 2000;15:722–730.
25. Fortin Y, Sullivan RM, Rangert BR. The Marius implant bridge: Surgical and prosthetic rehabilitation for the completely edentulous upper jaw with moderate to severe resorption: A 5-year retrospective clinical study. *Clin Implant Dent Relat Res* 2002;4:69–77.
26. Franchini I, Daverio L, Castellaneta R, Rossi MC, Testori T, Tosini T. Immediate and delayed “all-on-six” rehabilitation of the atrophic maxilla with tilted implants. *Eur J Dent Implantol* 2009;3:62–70.